

SURGICAL GINGIVECTOMY AND GINGIVOPLASTY ON UPPER ANTERIOR TOOTH

Ayuda Nur Sukmawati¹, Aulia Puspasari Ramadhani², Hidha Rahma Sintya Dewi²

1. Department of Periodontology, Faculty of Dentistry, Universitas Muhammadiyah Semarang

2. Dental Professional Program, Faculty of Dentistry, Universitas Muhammadiyah Semarang

Correspondence: drg.ayuda@unimus.ac.id

Received November 16th, 2024; 1st Revision February 14th, 2025; Accepted February 26th, 2025; Published online February 27th, 2025.

Keywords:

*Gingival Enlargement,
Gingival Pocket,
Gingivectomy*

Indonesian Journal of Dentistry
Volume 5 No 1 Issue 9 Year 2025 Pages 72-79
URL <https://jurnal.unimus.ac.id/index.php/IJD>
DOI <https://doi.org/10.26714/ijid.v5i1.16308>

ABSTRACT

Background: Gingival enlargement can be treated with periodontal therapy, starting with the initial phase therapy, which includes dental health education and scaling-root planning. When the enlargement persists after the initial treatment is carried out, a surgical procedure, namely gingivectomy, is needed.

Methods: A 22-year-old male patient came to RSGM UNIMUS complaining that his upper front gums appeared enlarged. The patient had been aware of the complaint since the examination during the scaling procedure two weeks ago. There was no pain in the enlarged gums, but they bled when brushing his teeth. The patient wanted to get treatment for his gums. The patient denied any relevant medical history and allergies.

Outcome: The gingivectomy in this patient improved the gingiva appearance and lengthened the clinical crown on the upper anterior teeth.

Conclusion: Gingivectomy was proven to be an effective surgical therapy to eliminate gingival enlargement and maintain the proportional gingival appearance, especially on the anterior teeth. However, considering the complexity of the case, more extensive mouth rehabilitation is required.

INTRODUCTION

Poor oral and dental hygiene can cause gingival inflammation, which can facilitate the buildup of plaque and calculus and will affect the prevalence of the severity of inflammation in gingiva. Non-optimal plaque control causes a buildup of supragingival plaque bacteria, which causes gingiva inflammation. The inflammation that occurs can cause gingival enlargement.¹ Gingival enlargement is a common symptom of gingival disease. Gingival enlargement is a condition that can cause aesthetic and dental hygiene problems.² Factors causing gingival enlargement can be local factors and systemic factors. Local factors include plaque accumulation accompanied by poor oral hygiene.³ The clinical appearance of healthy gingiva is coral pink, with a knife-edged margin, and the interdental papilla is pyramidal. Its consistency is firm and tightly positioned around the tooth. The gingiva margin is located at 1–2 mm coronally from the cemento-enamel junction (CEJ).⁴

Periodontal treatment begins with an initial phase therapy that includes dental health education (DHE) and scaling-root planning. If gingival enlargement does not subside after these treatments, a gingivectomy is required.⁵

Gingivectomy is the cutting of enlarged gingival tissue (hyperplasia) by removing pockets to eliminate pockets and inflammation and obtaining a physiological, functional, and aesthetic gingival shape. The aim is to eliminate pockets and gingival inflammation so that physiological, functional, and aesthetic gingiva is obtained, making it easy to maintain oral and dental hygiene.⁶

The most common etiology of gingival enlargement is due to the presence of bacterial plaque. Meanwhile, the predisposing factors for gingival enlargement are the presence of dental caries and crowded teeth.⁷ Crowded teeth can cause gingival enlargement, resulting in gingival pockets with or without attachment loss. Therefore, orthodontic treatment is needed to improve dental aesthetics by correcting crowded teeth and improving the gingiva.⁵

RESEARCH METHOD

A 22-year-old male patient came to RSGM UNIMUS with complaints that his upper front gums appeared enlarged (Figure 1.A-B). The patient had been aware of the complaint since the examination during the scaling procedure two weeks ago. There was no pain, but the gum bled when brushing his teeth. The patient wanted to get treatment for his gums. The patient denied any relevant medical history or allergies. He brushed his teeth twice daily during morning and evening showers, using a soft toothbrush and fluoride toothpaste.

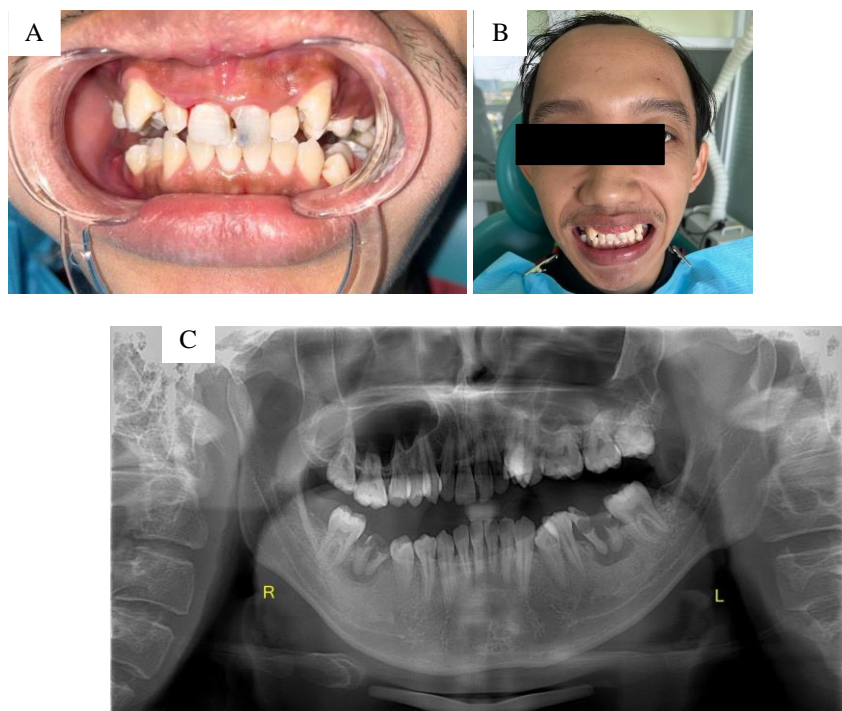


Figure 1. (A) Clinical photo (B) Photo of the patient smiling (C) Panoramic radiography examination.

The patient was diagnosed with plaque-induced gingival enlargement. Treatment planning involves the initial phase, eliminating the etiological factors by scaling and root planning. Then, an evaluation will be carried out at the next control visit. The results of the intraoral examination after the scaling and root planning showed that there were still signs of inflammation on teeth 12, 11, 21, and 22 (Figure 1.C). Therefore, the surgical phase continued with gingivectomy. Before the surgical procedure, teeth 12, 11, 21, and 22 were examined (Table 1) and clinical crown length measurements (Table 2).

Table 1. Results of intraoral examination

Information	OHI	O'Leary	Probing Depth											
			12			11			21			22		
			D	F	M	D	F	M	D	F	M	D	F	M
Visit 1	4,5	40,38%	5	2	4	3	3	5	4	4	3	4	3	4
Visit 2	2,49	37%	5	3	5	5	3	5	5	3	5	5	3	5
Visit 3	3,99	39,81%	4	3	3	5	3	4	5	3	5	3	2	5

Note: D: Distal, F: Facial, M: Mesial

Table 2. Pre-surgical clinical crown length

Tooth	12	11	21	22
Crown length	8 mm	10 mm	9 mm	8 mm

Treatment begins after checking vital signs and filling out informed consent. The gingivectomy procedure begins with asepsis using 10% povidone-iodine with a circular technique. The infiltration anesthesia was administered using 1 cc of pehacaine in the mucobuccal fold between teeth 22-21 and between teeth 11-12. Then a numb test was conducted to determine whether the anesthesia had worked (Figure 2). A 2 mm bleeding point was made using a probe and explorer, followed by outlining by connecting one bleeding point to another (Figure 3).

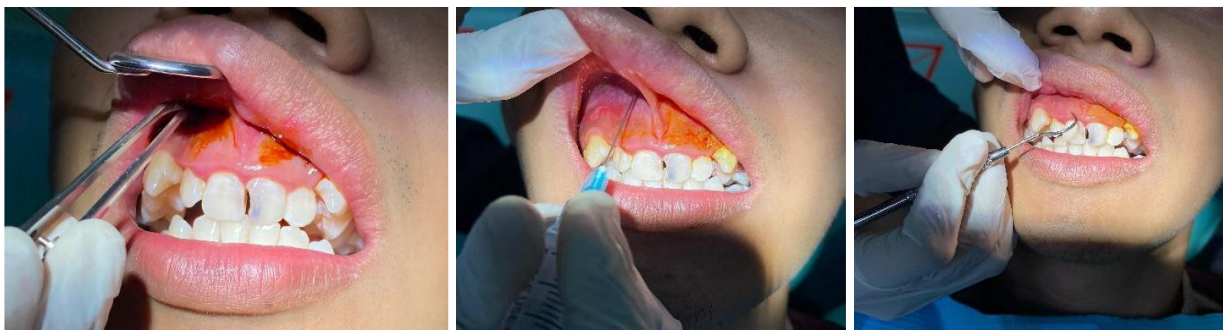


Figure 2. (A) Asepsis of the working area (B) Infiltration anesthesia (C) Numb test examination.

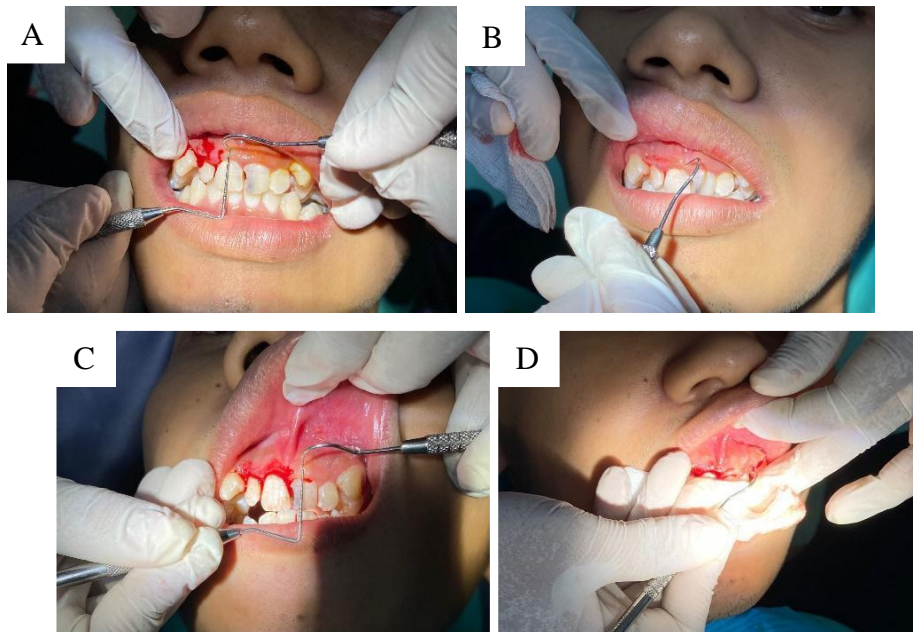


Figure 3. (A) Bleeding points for teeth 12 and 11 (B) Outline incisions for teeth 12 and 11 (C) Bleeding points for teeth 21 and 22 (D) Outline incisions for teeth 21 and 22.

An external bevel incision was done 1 mm apically from the bleeding point, forming a 45-degree angle coronally using blade number 15 and a discontinued incision technique starting from the distal to the mesial. Root planning was carried out to remove the remaining granulation tissue, necrotic cementum and calculus with Gracey curette #1-2 with the sharp part facing the tooth surface (Figure 4).

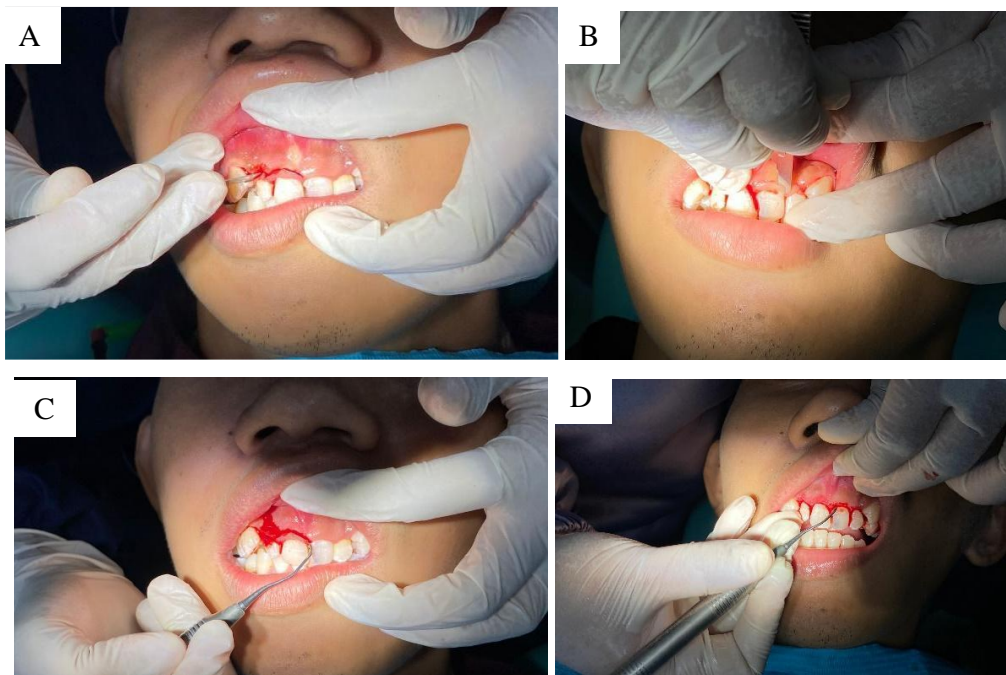


Figure 4. (A) Incision of teeth 12 and 11 using blade no. 15 (B) Incision of teeth 21 and 22 using blade no. 15 (C) Removal of granulation tissue of teeth 21 and 22 (D) Removal of granulation tissue of teeth 21 and 22.

After gingivectomy, gingival curettage was carried out on the interdental part of the same teeth, with Gracey curette #1-2 penetrating along the soft tissue with horizontal movements. Gentle finger pressure on the outer surface helps supports gingiva. The granulation tissue is removed with a scooping motion of the curette against the gingival wall. The area was irrigated with NaCl solution to remove debris, and then the tissue was gently pressed to the tooth surface, allowing the cessation of bleeding and adaptation of the soft tissue to the root surface (Figure 5).

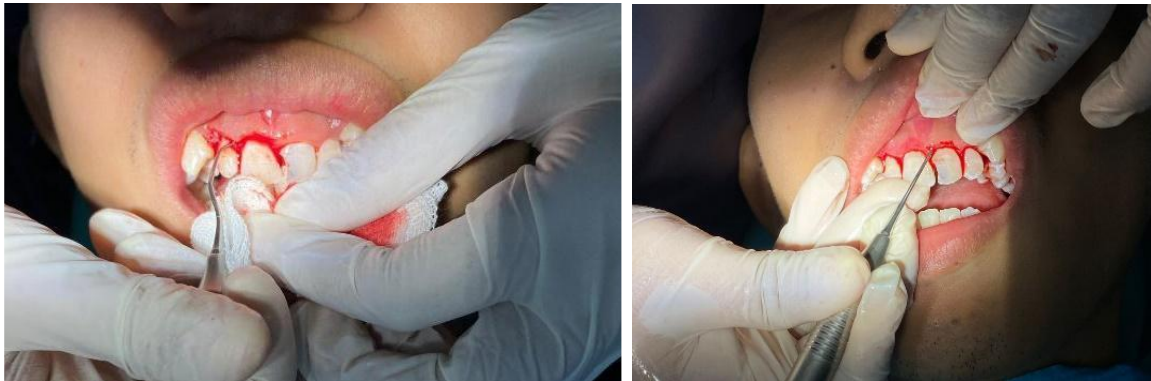

Figure 5. Gingival curettage between teeth 12 and 11, and gingival curettage between teeth 11 and 21.

Gingivoplasty was carried out to reshape the gingiva using a diamond round bur and using blade number 15. Bleeding was carefully controlled using gauze (Figure 6).

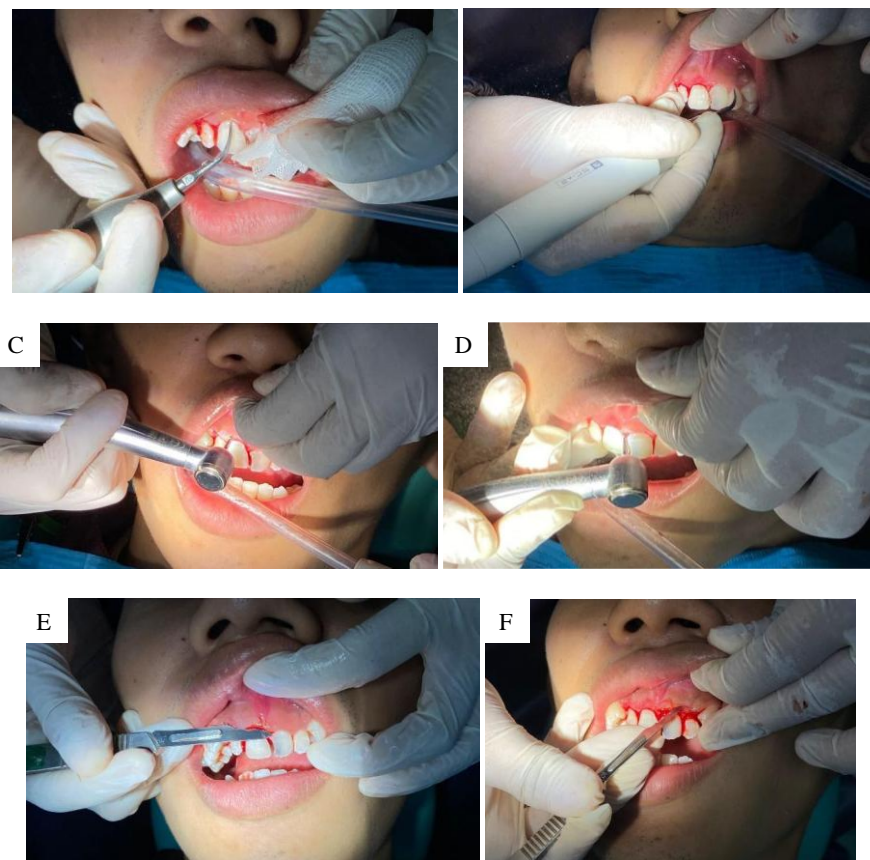


Figure 6. (A-B) Scaling and root planning on teeth undergoing surgery (C-F) gingivoplasty to reshape the gingiva using a diamond round bur and blade no. 15.

The periodontal dressing was manipulated and applied to the surgical area to protect the post-gingivectomy wound (Figure 7) and followed by prescribing analgesic and 0.12% chlorhexidine gluconate mouthwash. The patient was instructed for the follow-up visit two weeks after the surgery.

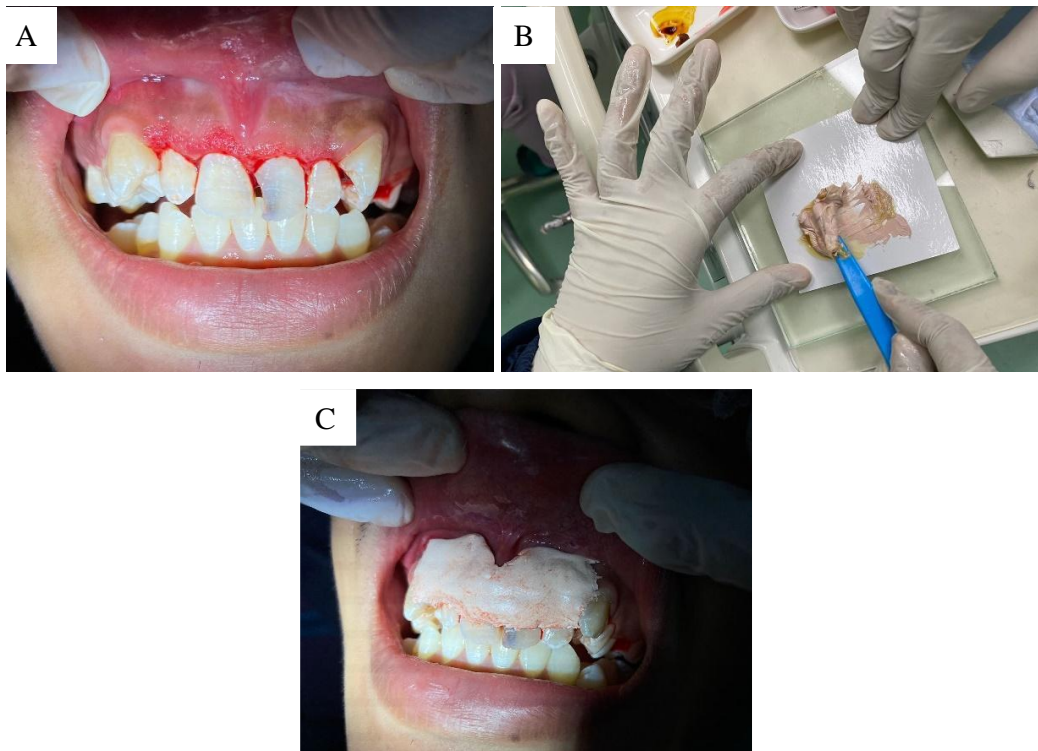


Figure 7. (A) Clinical picture after the procedure (B) manipulation of the periodontal dressing (C) application of the periodontal pack to the surgical area.

At the two-week recall visit, the patient had no complaints. The clinical crowns appeared longer. The probing depth inspection has not yet been carried out. The gingiva is in good condition, but the gingival margin is slightly rounded. There was minimum plaque accumulation (Figure 8).

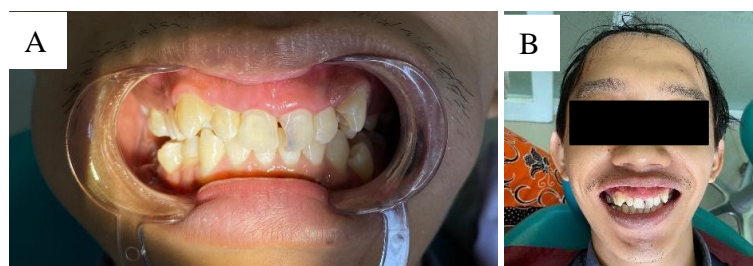

Figure 8. (A) Clinical crowns (B) Photo when the patient smiles.

DISCUSSION

Poor oral hygiene causes plaque buildup and leads to periodontal problems and tooth decay. Factors that promote plaque buildup and retention include poor oral hygiene, abnormal relationships between adjacent and opposing teeth, lack of tooth function, improper restorations, orthodontic treatment, and habits. Poor oral hygiene is associated with the recurrence of gingival enlargement. Therefore, there is a close relationship between oral hygiene and the prevention of gingival

enlargement relapse. Proper orthodontic treatment vastly improves plaque control in crowded teeth.⁸ Caries on the patient's teeth might also provoke gingival regrowth after gingivectomy due to the accumulation of bacteria.

Gingival enlargement occurs due to proliferation of blood vessels and fibroblast cells. In gingival enlargement, the production of type-1 collagen, heat-shock protein (HSP)-47 increases. This condition is followed by a decrease in matrix metalloproteinase (MMP)-1 and MMP2 levels. The decrease in both MMPs results in a decrease in the physiological mechanism of extracellular matrix degradation.⁸ Gingivectomy and gingivoplasty are periodontal surgical procedures that remove pockets and gingival inflammation to obtain physiological, functional, and aesthetically pleasing gingiva.⁹ Gingivectomy and gingivoplasty help remove gingival overgrowth and maintain good oral hygiene, crucial for preventing plaque buildup.¹⁰

Management of gingival enlargement can be divided into two phases: non-surgical and surgical. The non-surgical phase is the first phase, in which the etiological factor must be removed, along with mechanical therapy consisting of scaling and root planning. This phase usually helps resolve the inflammatory component. Surgical procedures such as gingivectomy and gingivoplasty are performed later to remove the fibrotic component and restore the normal gingival contour.¹¹

Gingivectomy, curettage, or other surgical procedures will be performed when the plaque index is less than 10% so that optimal healing can be achieved, and recurrence can be prevented after the surgery.¹² In cases where crowded teeth are present, orthodontic treatment is recommended so that it will make it easier for patients to maintain cleanliness and reduce relapses after gingivectomy and curettage.

The patient was prescribed 500 mg of mefenamic acid and 0.12% chlorhexidine gluconate mouthwash. The patient was given analgesics after gingivectomy and curettage for pain management after surgery. Pain management generally uses analgesics such as opioids and NSAIDs (Non-Steroid Anti-Inflammatory Drugs). Treatment of mild acute pain is NSAIDs, moderate acute pain using NSAIDs and weak opioids, while severe pain requires strong opioids such as morphine and a combination with NSAIDs.¹³

CONCLUSION

Although the gingivectomy in this case managed to lengthen the clinical crown, it showed less-than-desirable results due to several limitations. Existing caries and crowded teeth require further intervention before the surgical gingivectomy can produce ideal results.

ACKNOWLEDGMENTS

We want to express our gratitude to our patient, who has been very cooperative and willing to spend time carrying out gingivectomy treatment from start to finish so that we can complete this research article.

REFERENCES

1. Sukanti E, Eriyati, Aflinda Yenti, Muhammad Faisal Td. Hubungan Kebersihan Gigi Dan Mulut Dengan Kondisi Gingiva Pada Siswa Smp. *J Menara Med.* 2024;6(2):336–43.
2. Ramadhany, Eka Pramudita. 2019. Enlargement Pada Pasien Perawatan. 15:6–9.
3. Satrio R, Ekawati EY, Ilmu B, Mulut P, Gigi K, Kedokteran F, et al. Laporan Kasus: Drug-Induced Gingival Enlargement Akibat Konsumsi Amlodipin. *JKG Unej.* 2020;17(1):1–3.
4. Bathla S. *Textbook of Periodontics.* Vol. 1. New Delhi: Jaypee Brothers Medical Publishers; 2017.
5. Siti Sopiadin, Ira Komara, Ina Hendiani IMSP. Gingivectomy Of Gingival Enlargement In Orthodontic Patient: (Case Report). *Cakradonya Dent J.* 2019;13(1):32–8.
6. Wan K-F, Wong MMC. Stress and burden faced by family caregivers of people with schizophrenia and early psychosis in Hong Kong. Vol. 49, *Internal Medicine Journal.* Wiley; 2019. p. 9–15.
7. Suwandi T. Epulis Gravidarum Dan Penatalaksanaannya. *Progr Stud Kedokt Gigi, Univ Trisakt.* 2018;1–10.
8. Prahasanti C. *Proceeding: The 3rd Periodontic Seminar (PERIOS 3): Cosmetic and Functional in Modern Periodontic.* Surabaya: Airlangga University Press; 2017.
9. Widagdo AK, Murdiastuti K. Gingivektomi Menggunakan Scalpel dan Electrocautery pada Perawatan Gingival Enlargement Wanita Pubertas. *Maj Kedokt Gigi Klin.* 2016;1(1):1.
10. Ratnawati ID, Pratiwi R, Gigi FK, Periodontologi J, Islam U, Agung S. Gingivektomi konvensional untuk pembesaran gingiva kronis dalam perawatan ortodontik : laporan kasus. 2023; 10:69–75.
11. Amalia M, Ningsih CA, Meydhiono W. Management of Bacterial Plaque-Induced Gingival Enlargement: Case Report. *Interdental J Kedokt Gigi.* 2024;20(1):156–63.
12. Andriani I. Perawatan Pembesaran Gingiva dengan Gingivektomi Treatment Gingival Enlargement by Gingivectomy. *Mutiara Med.* 2009;9(1):69–73.
13. Darajatun LA, Alifiar I, Nofianti T. Gambaran Penggunaan Analgetika Pada Pasien Pasca Bedah Di Ruang Iii Dan Melati Lantai 4 Rsud Dr. Soekardjo Kota Tasikmalaya. *Fitofarmaka J Ilm Farm.* 2017;7(1):29–35.