



REPORT MANAGEMENT OF BENIGN NEOPLASM AR GLOSSUS ET VESTIBULUM IN PATIENTS AT SULTAN FATAH HOSPITAL DEMAK

Syarifah Nova Amiza Zam¹, Aulia Adila Rizqi¹, Rif'an Irham Maulana¹, Hety Rahmawati¹, Arkhamatul Wafiroh¹, Laily Rahmah

¹Department Oral and Maxillofacial Surgery, Faculty of Dentistry, Universitas Muhammadiyah Semarang

Correspondence: auliaadilqi65@gmail.com

Received March 22nd, 2024; 1st revision August 10th, 2024; Accepted August 14th, 2024; Published online August 19th, 2024.

Keywords:

Benign Neoplasm, Excision, Tumor, Tongue

Indonesian Journal of Dentistry
Volume 4 No 2 Issue 3 Year 2024 Pages 60-65
URL <https://jurnal.unimus.ac.id/index.php/IJD>
DOI <http://dx.doi.org/10.26714/ijid.v4i2.14386>

ABSTRACT

Background: Tumor is an abnormal mass of tissue in the body. There are 2 types, benign tumors and malignant tumors. Manifested by a lump, although some cases show ulceration, pain and bleeding. The size of the lesions ranged from 0.8 – 5.0 cm (mean 2.6 cm) and asymptomatic. Based on Riskesdas's data, prevalence of tumors in Indonesia shows an increase from 1.4/1000 population in 2013 to 1.79/1000 population in 2018.

Case: A 62-year-old male patient came to the Oral Surgery Clinic at Sultan Fatah Hospital, Demak on April 28, 2023, with complaints of lumps on the edges of the tongue, gums with similar size of corn kernels and similar color with blood since last 1-2 years.

Case management: The patient underwent excise the tumor as well as perform dental odontectomy 24, 27, 38, and 43 under general anesthesia. On the 7th day, the patient underwent post-operative control and off hecting and spooling. Result: The patient did not complain of pain and was able to open his mouth well.

Conclusion: In this case, subjective, objective, and supporting examination cause *benign tumors*. The treatment carrier out is excision tumor and odontectomy of 24, 27, 38, and 43.

INTRODUCTION

A tumor is a mass of tissue that is abnormal, overgrown, uncoordinated with normal tissue, grows continuously even though the stimuli that caused it has disappeared, and cannot be controlled by the body. Neo means new, plasia means growth or division, so neoplasia refers to the growth of new cells, which are different from the growth of normal cells around them. Based on Riskesdas data, the prevalence of tumors in Indonesia shows an increase from 1.4 per 1000 population in 2013 to 1.79 per 1000 population in 2018.¹

Tumors based on their nature are divided into benign tumors *and* malignant tumors (*malignant tumors*). *Malignant tumors* are also referred to as cancers that have the potential to attack or damage surrounding tissues and cause metastasis. *Benign tumors* such as those reported in this case do not invade the surrounding area and do not form metastases, but can locally grow to large.² The main difference between the two is that malignant tumors are more dangerous and fatal so they can result in

death. Benign tumors can only cause death directly related to the location of their dangerous growth, for example tumors in the neck that can compress the airways.

Clinical symptoms are visible in the presence of a lump, although some cases show ulceration, pain and bleeding. The size of the lesions ranges from 0.8 – 5.0 cm (average 2.6 cm) and the lesions that appear are usually asymptomatic. The treatment of *Benign Neoplasm* is the excision of the tumor with general anesthesia. Excision is performed by taking the entire tumor mass around the edge of the lesion with approximately 2 – 3 mm from the edge of the lesion. Then the excision scar wound is stitched up as much as possible.

CASE REPORT

A 62-year-old male patient came to the Oral Surgery Polyclinic of Sultan Fatah Hospital, Demak Regency on April 28, 2023, with complaints of lumps on the edges of the tongue and gums the size of corn kernels, similar in color to the surrounding area since the last 1-2 years. When the mass was touched, it felt supple, there was a wound at the edge of the mass, and it was not easy to rupture but was currently bleeding. In addition, the patient also complained of painful teeth and the pain was felt to be missing in the left back upper teeth, right lower canines, and left lower back teeth. Before the patient checked his condition at the Oral Surgery Poly, 1 week before the patient had checked at the Health Center and the patient was given a referral to go to the hospital.

The patient had an examination of the teeth at the Clinic 1 month ago. The patient stated that he brushed his teeth 2 times a day while taking a shower in the morning and evening, and the patient did not stay. The patient has no history of systemic disease.³ Initially, patients began to feel complaints since the last 1-2 years. The beginning of the lesion is in the form of small lumps near the tongue and gums that are getting bigger and bigger, there is no pain, but until finally the patient feels the lump enlarged and feels uncomfortable. The patient had never treated the complaint before.

Previously, patients had never experienced pain like this. The patient admitted to having cavities problems, in the patient's family no one had ever suffered from a similar disease before. The patient when coming to the Poli with *a state of compos mentis* (full consciousness) is then examined for blood pressure of 147/82 mmHg, temperature 36° C, respiratory examination 20 x/minute, pulse examination 108 x/minute. From the results of laboratory examinations, eosinophil 3%, neutrophil 59%, MCHC 36.7% were obtained. From the results of the panoramic radiography examination, it appears that there is a round opacity parallel to the 38th tooth.⁴

Panoramic radiographic examination showed a round opacity parallel to the 38th tooth. The provisional diagnosis obtained was *benign neoplasm* in the vestibulum and multiple necrosis of the tooth pulp 24, 27, 38, 43. The planned treatment action is to excise the tumor as well as perform dental

odontectomy 24, 27, 38, and 43 under general anesthesia. The first thing that must be considered when performing surgery is consent or *inform consent*, communicate to the patient or the patient's family the basic diagnosis of the disease and the stages that will be carried out when the surgery is carried out, educate the patient about the risks if treatment is not carried out and what alternatives can be done other than surgery and estimated surgery costs.

The patient's preparation is that the patient is instructed to pray first before the surgery is performed, then the patient sleeps in the operating room relaxed and comfortable, anesthesia is carried out to the patient by the anesthesiologist in charge during the operation, then incubation of the patient, then perform asepsis and antisepsis using povidone iodine, and do draping, then attach an oropharyngeal pack and perform adrenaline injections on the patient's patient The operator's preparation is to wash hands according to WHO, the operator and the patient are in a sterile state, the operator prays first and reads the time out before the surgery is carried out by the oral surgeon who handles the case, namely drg. Syarifah Nova Amiza Zam, Ph.D, Sp BM, the operator excisates and takes lesions or tissue from the mass of dental tumors then irrigated and hected, followed by odontectomy or tooth extraction 24, 27, 38, and 43.⁵ Then, bleeding control is carried out by hecting the work area to close the wound.

On the 7th day, the patient underwent post-operative control and *off hecting* (suture removal) and *spooling*. The patient did not complain of pain and was able to open his mouth well.

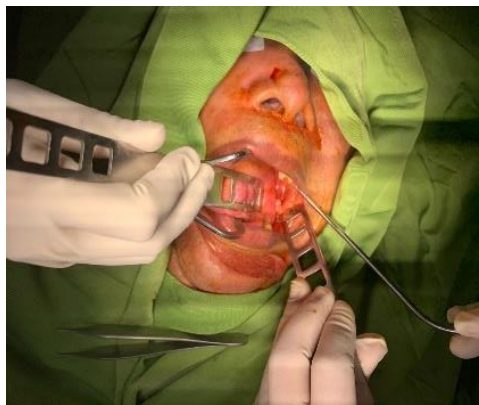


Figure 1. Intraoral Overview before Surgical Procedures

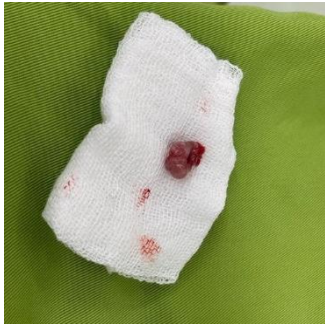

Figure 2. Tumor Masses That Have Been Excised

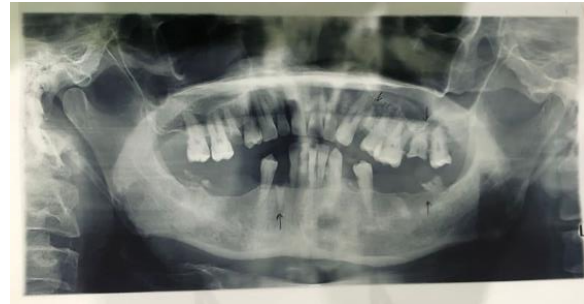

Figure 3. Panoramic Examination Results

DISCUSSION

Based on the results of the subjective examination, objective examination, and supporting examinations carried out, the diagnosis in this case is that the patient has Benign *Neoplasm ar glossus et vestibulum*. The treatment plan that will be carried out is excision of the tumor and suturing after the procedure. A tumor is a mass of tissue that is abnormal, overgrown, uncoordinated with normal tissue, grows continuously even though the stimuli that cause it has disappeared, and cannot be controlled by the body.⁶

Based on the results of the examination that has been carried out, the patient complained that there were lumps on the edges of the tongue and gums as big as corn kernels, the color is like the surrounding area since the last 1-2 years. When the mass was touched, it felt supple, there was a wound at the edge of the mass, and it was not easy to rupture but was currently bleeding. In addition, the patient also complained of painful teeth and the pain was felt to be missing in the left back upper teeth, right lower canines, and left lower back teeth.⁷

Tumors based on their nature are divided into benign tumors *and* malignant tumors (*malignant tumors*). Malignant tumors are also referred to as cancers that have the potential to attack or damage surrounding tissues and cause metastasis. *Benign tumors* such as those reported in this case do not invade the surrounding area and do not form metastases, but can locally grow to large.⁸ The main difference between the two is that malignant tumors are more dangerous and fatal so they can result in death. Benign tumors can only cause death directly related to the location of their dangerous growth, for example tumors in the neck that can compress the airways. Clinical symptoms are visible in the presence of a lump, although some cases show ulceration, pain and bleeding. The size of the lesion ranges from 0.8 – 5.0 cm (average 2.6 cm) and the lesions that appear are usually symptomatic.

Based on the histological picture of benign tumors on the surface of the tongue there are small protrusions called papilla lingualis. This papilla consists of four types, namely papilla filiformis, papilla fungiform, papilla circumvallate, and papilla foliata. The keratinized flat-coated epithelium on the tongue is lined by the filiformis papilla and the circumvallate papilla.⁹ The filiformis papilla does

not have taste buds so the epithelium underneath undergoes a keratinization process caused by friction during the digestive process. Non-keratinized flattened epithelium is lined by papilla foliata and papilla fungiformis. The function of this epithelium is generally as a taste bud or taste.

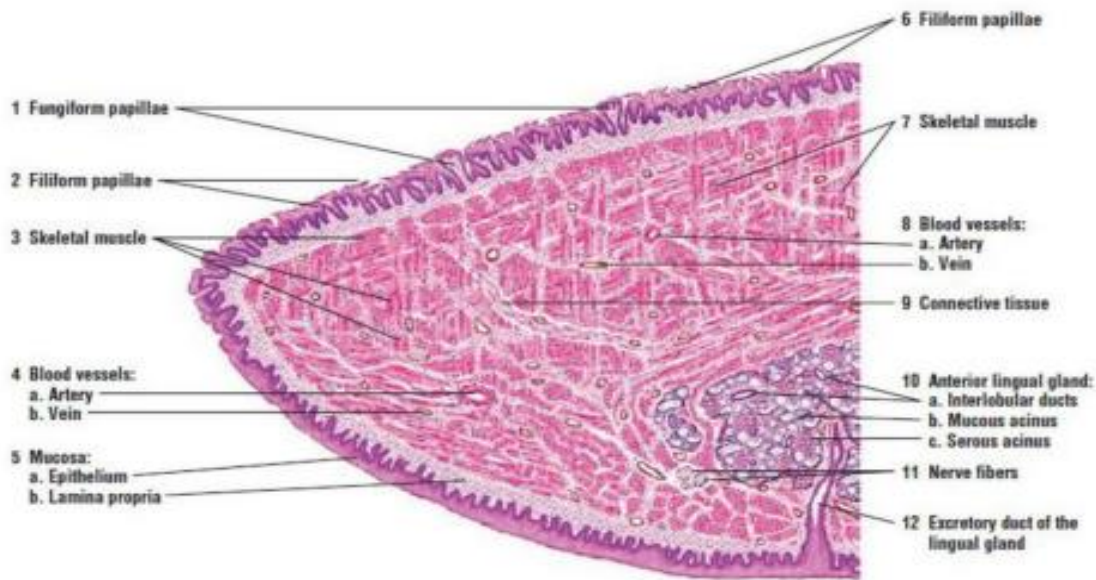


Figure 4. Structure of Tongue Histology

The management carried out in this case after an anamnesis examination, initial assessment, secondary assessment, and overall and localized objective examination, is a supporting examination to ensure the patient's overall condition. The supporting examinations carried out were rotophotic photos and laboratory examinations with macroscopic results, preparations from mandibular tumors in the form of dense and microscopic reddish tissue diameter 1 cm showed tissue coated with keratin-complex squamous epithelium, growing papillomatous, acanthosis, hyperplastic, accompanied by fibrous tissue stroma that were swollen, hyperemic, without signs of malignancy.

There are various types of tumor treatment which are generally a combination of surgery, radiotherapy, and chemotherapy. Benign tumors that cause disorders and if possible are usually removed through surgery or surgery.

Case management based on anamnesis, clinical examination and supporting examination stated that the clinical diagnosis is *Benign Neoplasm ar glossus et vestibulum*. Then an incision biopsy was carried out and the results of histopathological examination were obtained in accordance with the clinical diagnosis, namely *squamous papilloma* which is a benign tumor/*benign neoplasm* and is planned to be carried out definitive therapy of tumor excision with general anesthesia. Patients in surgery under general anesthesia. After intubation via nasotracheal, a mouth gag (dingman) is installed to extend access to the palate. Access and visibility are the keys to the effectiveness of the excision

that will be carried out. Adrenaline infiltration injection is performed for vasoconstriction of blood vessels, the surrounding mucosa is marked then extensive excision is carried out with a scalpel and blunt dissection with a rasparatorium and scissors. Next, action was taken in the form of taking the entire tumor mass around the edge of the lesion with approximately 2 – 3 mm from the edge of the lesion. During surgery was found a clearly demarcated elastic mass, with a tumor mass measuring 4 × 3 cm, 3 × 2 cm, the same color as the surrounding tissue, round, single nodule, immobile, rather hard palpation.¹⁰ The excision scar wound is stitched up as much as possible. The patient is hospitalized and the next day after the general condition is good the patient can be discharged.

CONCLUSION

Benign neoplasms or benign tumors are localized tumors with a slow-growing mass. These tumors do not invade the surrounding area and do not form metastases but can locally grow to be large. The treatment of *Benign neoplasms* is the excision of the tumor with general anesthesia. Excision is performed by taking the entire tumor mass around the edge of the lesion with approximately 2 – 3 mm from the edge of the lesion. Then the excision scar is stitched up as much as possible to control postoperative bleeding. On the 7th day, the patient performed *postoperative* control and *off hecting*.

BIBLIOGRAPHY

1. Yasa WS, Nusantara Putra IMHC, Guspiari K. INTRAORAL LYPHOMA ON THE MENTAL REGION: A Case Report. *Interdental J Kedokt Gigi*. 2022;18(2):100–5.
2. Błochowiak K, Farynowska J, Sokalski J, Wyganowska-Świątkowska M, Witmanowski H. Benign tumours and tumour-like lesions in the oral cavity: A retrospective analysis. *Postep Dermatologii i Alergol*. 2019;36(6):744–51.
3. Soeprajogo MP. Penatalaksanaan Tumor Adenoma Pleomorfik Kelenjar Lakrimal. 2019;1(1).
4. Sakamoto Y, Oyama G. Giant Lipoma Presents from the Buccal Vestibule. *Case Rep Dent*. 2020;2020(Figure 3):3–6.
5. Rivki M, Bachtiar AM, Informatika T, Teknik F, Indonesia UK. *Oral Surgery*.
6. Kaur R, Kler S, Bhullar A. Intraoral lipoma: report of 3 cases. *Dent Res J (Isfahan) [Internet]*. 2011;8(1):48–51. Available from: <http://www.ncbi.nlm.nih.gov/pubmed/22132015><http://www.pubmedcentral.nih.gov/articlerender.fcgi?artid=PM C3177381>.
7. Samad S, Arumsari A, Rizki KA. Penatalaksanaan Adenoma Pleomorfik di Palatum Pada Pasien Dewasa Muda Dengan Biopsi Eksisi. *Mkgk*. 2016;2(3):132–6.
8. Balaji S. *Textbook of Oral and Maxillofacial Surgery*. 2007.
9. Monheim LM. Local anesthesia. Vol. 13, *The Journal of Prosthetic Dentistry*. 1963. 933–939 p.
10. Yudhasoka KL, Sjamsudin E, Arumsari A, Rizki KA. Eksisi pleomorfik adenoma pada palatum keras. *J Kedokt Gigi Univ Padjadjaran*. 2019;31(2):82–7.