



## Adenomyosis, Multiple, and Intraligamentary (Sacro Uterine) Fibroids: A Rare Case

Muhammad Anas<sup>1</sup>, Ari Pudji Prasetyo<sup>2</sup>, Ahmad Mochtar Jamil<sup>3</sup>

<sup>1</sup>Departement of Obstetric Gynecology, Faculty of Medicine, Universitas Muhammadiyah Surabaya, Surabaya, East Java, Indonesia

<sup>2</sup>Departement of General Surgery of RSI Hasanah Muhammadiyah Mojokerto, Mojokerto, East Java, Indonesia

<sup>3</sup>Faculty of Medicine, Universitas Muhammadiyah Surabaya, Surabaya, East Java, Indonesia

Article Info	Abstract
<p><b>Article history:</b> Received 23 October 2023 Revised 26 October 2023 Accepted 26 October 2023 Available online 16 November 2023</p> <p><b>Keywords:</b> Sacrouterine; intraligament; myoma uteri; myomectomy</p> <p><b>Correspondence:</b> <a href="mailto:muhanasjamil@yahoo.co.id">muhanasjamil@yahoo.co.id</a></p> <p><b>How to cite this article:</b> Muhammad Anas, Ari Pudji Prasetyo. Adenomyosis, Multiple, and Intraligamentary (Sacro Uterine) Fibroids: A Rare Case. MAGNA MEDIKA Berk Ilm Kedokt dan Kesehat. 2023; 10(2): 258–264</p>	<p><b>Background:</b> Uterine leiomyomata, often known as fibroids, are frequently accompanied by symptoms that are common to a variety of different pelvic disorders. When considering treatment choices, it is critical to correctly identify myomata and rule out other disorders, including malignancies. In this case report, the author emphasizes the difficulty in establishing a preoperative diagnosis and the actions taken during the operation.</p> <p><b>Case Presentation:</b> Female, 46 years old, has three children who live with two children. She was complaining of left abdominal pain and penetrating to the waist. There were no complaints of defecation or urination. A mass in the lower abdomen, solid springy, and half of the symphysis center tend to the right with limited mobility. The preoperative diagnosis is pedunculated uterine myoma. It was decided to do a Supravaginal Hysterectomy and Bisalpingo-forectomy. The pelvic cavity still looks bulging, and exploration was carried out to find uterine myomas of the intrasacrouterina ligament. Then, it was decided to do a Myomectomy.</p> <p><b>Conclusion:</b> Pedunculated uterine myoma intrasacrouterina ligament performed Supravaginal Hysterectomy and Myomectomy</p>

2023 MAGNA MEDIKA: Berkala Ilmiah Kedokteran dan Kesehatan with CC BY NC SA license

## INTRODUCTION

Uterine leiomyomata, often known as fibroids, are frequently accompanied by symptoms that are common to a variety of different pelvic disorders. When considering treatment choices, it is critical to correctly identify myomata and rule out other disorders, including malignancies. Several imaging modalities can help confirm a myomata diagnosis. When choosing an imaging technique, it is essential to consider both the process's benefits and expenses. Imaging can provide information about the precise location of myomata, which can influence therapy options. Myomata can be characterized by their location within the uterus and their stage of degeneration. With the growing popularity of uterine-conserving surgery, a precise diagnosis of myomata is more critical than ever<sup>1</sup>.

Uterine fibroids are benign monoclonal tumors of the uterus's smooth muscle cells that usually develop during reproductive years. Studies have discovered that women of African heritage are more prone to it, and the critical elements responsible for its incidence have yet to be identified. The study comprised 271 consenting females between 18 and 55 who were getting ultrasound scans at the study location. Fibroid prevalence was 33.9 %, with individuals aged 31 to 35 years (26.4%) having the highest frequency. The most prevalent type of ultrasound scan was for multiple fibroids with two or more nodules (64.8 %). Intramural was the most common form, accounting for 61.9 percent of all cases. The anterior wall is the most common location for tumors in the uterus (14.4 %). The fibroid's kind and location were primarily

intramural and on the uterus's anterior wall. In this study, the prevalence of uterine fibroids was determined to be 33.9 percent, with nulliparous women having the most remarkable rate of uterine fibroids<sup>2</sup>.

In this case report, the author emphasizes the difficulty in establishing a preoperative diagnosis and the actions taken during the operation.

## CASE REPORT

Female, 46 years old, she has three children who live with two children. The youngest child is 11 years old. The woman used operative contraception tubectomy when giving birth to her last child. Menstruation smoothly for three days. Last menstrual period: 15 November 2021. She was complaining of left abdominal pain and penetrating to the waist. There were no complaints of defecation or urination. In 2019, an ultrasound was performed with a diagnosis of uterine myoma.

The physical examination: head and neck within normal limits, chest, lung, and heart within normal limits, the abdomen is flexible, there is a mass in the lower abdomen, solid, springy, half of the symphysis center tends to the right with limited mobility, extremities within normal limits. The local gynecological status: vaginal vulva within normal limits, palpable mass behind the vagina, firm, painless, limited mobility, uterus at the level of the center of the symphysis shifted to the right with limited mobility fused with the mass behind the vagina, smooth cervix, pulled upward on the right, left and right parametrial adnexa no abnormality is found. The results of the laboratory examination are shown in Table 1.

Table 1. Laboratory Result Examination

Parameter	Value
Hemoglobin	15.2g/dL,
Hematocrit	25%,
Leukocytes	4,300x10 <sup>3</sup> /μL,
Platelets	295,000 x10 <sup>3</sup> /μL,
Neutrophil/lymphocyte ratio	2.18,
Erythrocyte sedimentation rate	10/21 mm/hour
Bleeding time	3 minutes
Clotting time	10 minutes
Random blood sugar	105g/dL
SGOT	18 U/L
SGPT	17 U/L
Basal Urea Nitrogen	18.8 mg/dL
Serum Creatinine	0.71 U/L
Covid-19 antigen swab	Negative

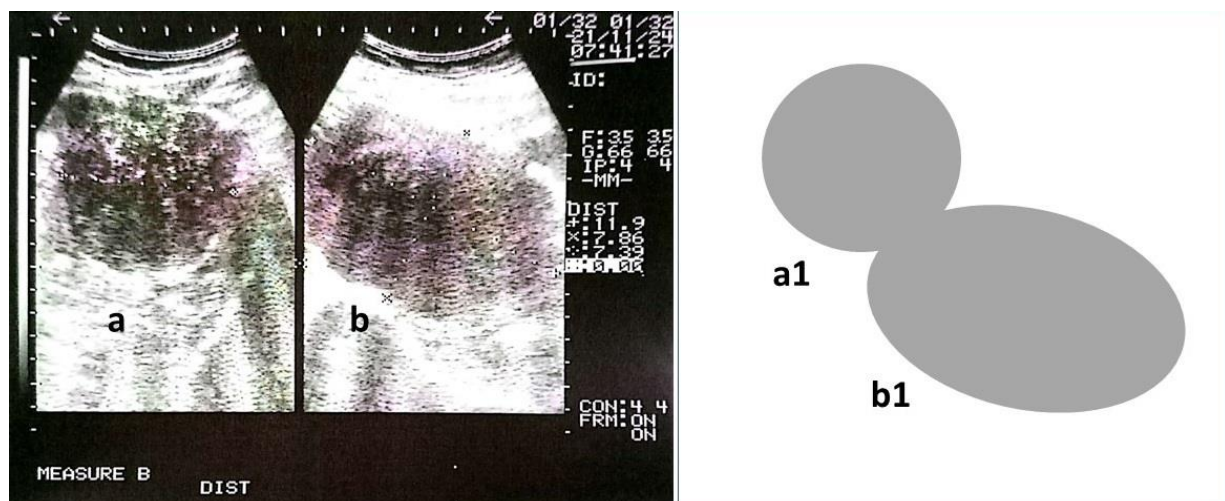


Figure 1. Ultrasonography. Left side, two-piece myoma uteri, a. diameter 7.39 cm, b. dimension 11.9x7.39cm. Right side, diagrammatic of the two of myoma uteri.

The results of the chest examination X-ray were within normal limits. The ultrasound examination showed two masses with a diameter of 7.8 cm and 11.3 cm with a suspicious position perpendicular to myoma uteri, as shown in Figure 1. The preoperative diagnosis is pedunculated uterine myoma.

The uterus was enlarged and widened during the operation, especially in the uterus's cervical area. The right and left ovaries are within normal limits. The right and left tubes are affixed with mow rings. It was decided to do a Supravaginal Hysterectomy and Bilateral oophorectomy. Double clamps were performed on the right side of the uterus, the

infundibulopelvic ligament was cut, and the nipple was sutured. It is followed by clamping and cutting the broad ligament to the uterine artery and performed on the left side of the uterus with technical difficulties due to widening the cervical area and shortening the broad ligament area.

After the uterus and right and left parametrial adnexa were removed, a mass filled the entire pelvic cavity, and it still oozed at the stomp

cervix at the right site. After exploration, no bleeding was found, followed by a small incision on the top of the bulging mass. It appears a white, shiny, dense mass that was chewy was carried out by opening the extraperitoneal cavity wider. So that a second mass was obtained with a size of 12 cm extracted with a myoma drill, a myomectomy was performed, which was intraligamentary at the sacrouterina and enlarged to fill the entire pelvic cavity.

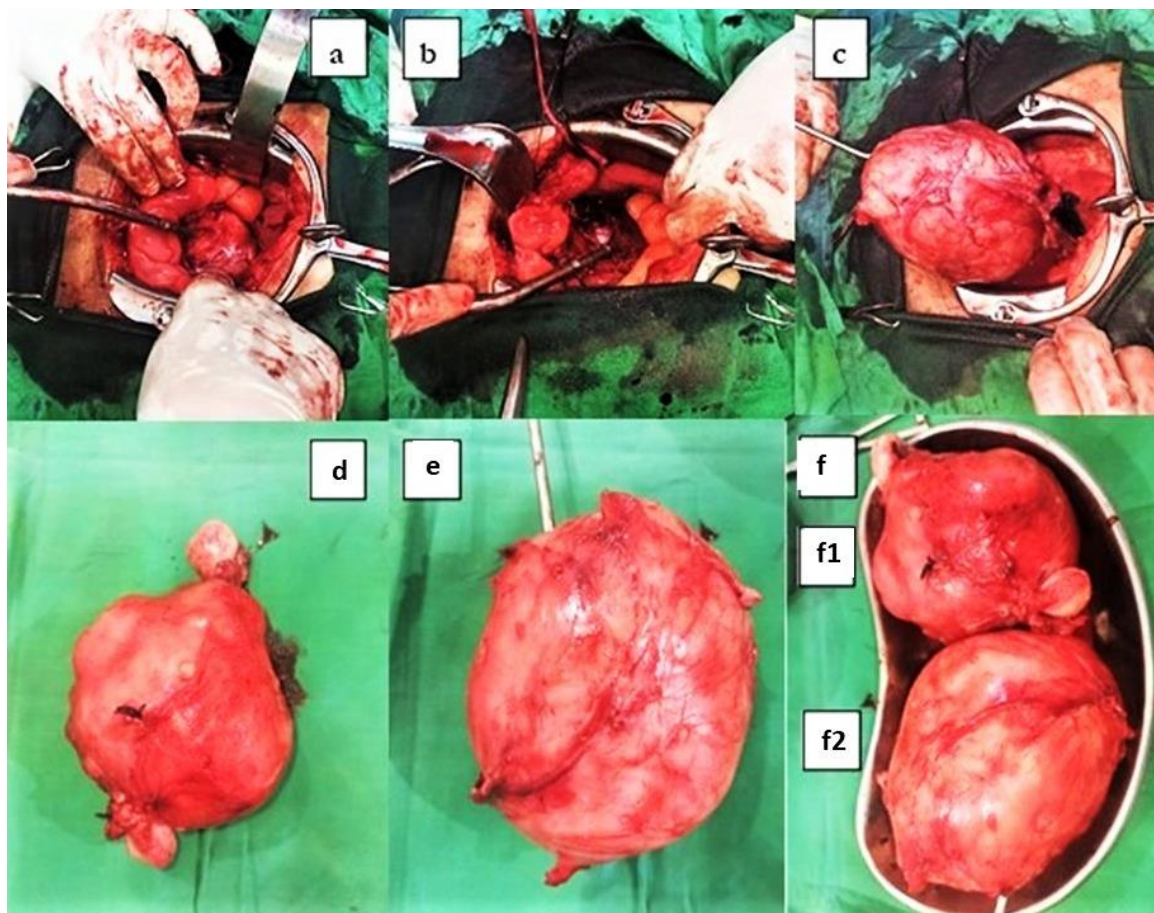


Figure 2. Pictures of myoma uterine mass during surgery. a. After removing the intra-abdominal uterine myoma mass, the abdominal cavity's appearance, the pelvic area still looks full and bulging, b. The dome of the cavum pelvis incision is made to see its contents after aspiration has been carried out. A shiny white solid mass appears in the hole. c. The second myoma uteri mass was removed from the pelvic cavity in the area of the sacrouterina ligament. d. the picture of myoma uteri in the abdominal cavity. e. the picture of myoma uteri in the retro-abdominal cavity, especially at the pelvic cavity on the sacrouterina ligament. f, f1, and f2. The two myoma-uterine in the intraabdominal and retroabdominal cavity.



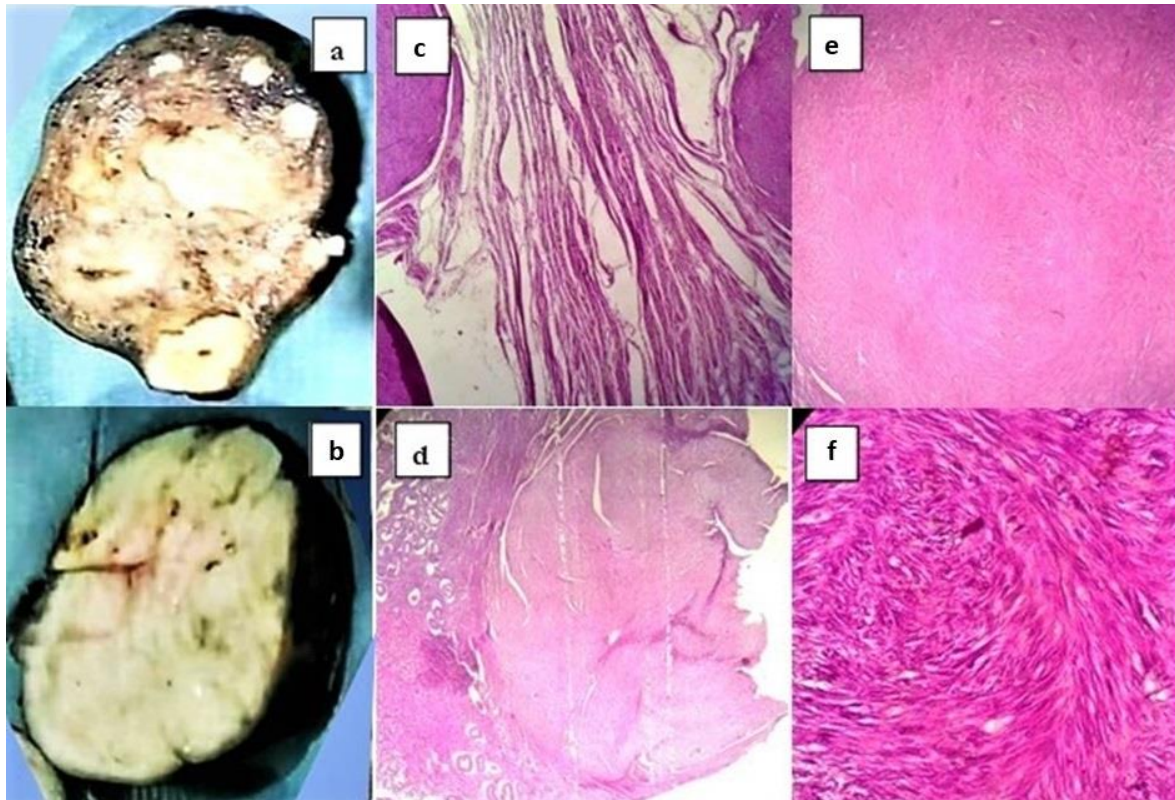


Figure 3. Macroscopic and Microscopic Pictures of Uterine Myoma. a, and b. Macroscopic picture of myoma uterine, a. intraperitoneal mass, b. retroperitoneal mass (intrasacroterina ligament). c, d, e, and f, Microscopic picture of myoma uterine, c, d, e, and f. intraperitoneal mass. e, and f. retroperitoneal mass.

### Description of pathology anatomy results from two materials from the operative procedure:

#### Material 1, Macroscopic picture of first material as Figure 3a:

It is one piece of tissue in a uterus weighing 400 grams and dimensions 8.5x8.5x7.5 cm. On the slices appear multiple intramural tumors, diameter 0.3-7 cm thick, spongy gray-brown with clear boundaries. Adnexa 1 consists of a tube of 5.5 cm, a diameter of 0.7 cm, and an ovary of 2.5x2.2x1 cm. There is a soft mass in the form of greenish jelly. Adnexa 2 consists of a tube of 4.5 cm, a diameter of 0.7 cm, and an ovary of 3.5x2.5x0.9 cm. There was a soft mass in the form of greenish jelly. It is partially processed in five blocks.

#### Microscopic picture of the first material as Figure 3c, d, e, and f:

Endometrium: proliferative gland phase with dense stroma.

Myometrium: multiple uterine myoma tumors were found with mitosis 0/10 high-power fields (HPF), and no malignant cells were found in this preparation. Adnexa 1 & 2: Ovaries have cyst follicles and corpus Albicans. Tuba: Within normal limits

**Conclusion of material 1:** Uterine tumor, supravaginal hysterectomy bilateral salpingo-oophorectomy (SVH BSO) is Multiple myoma uteri intramural with Adenomyosis.

#### Material 2, Macroscopic picture of second material as Figure 3b:

One piece of tissue weighing 550g, dimension 12x9x8.5 cm, thick spongy, gray-brown. It was further processed partially in 1 block.

### **Microscopic picture of the second material as Figure 3e and f:**

In the form of a demarcated uterine tumor consisting of a proliferation of spindle cells arranged in a whirlpool. Mitosis 0/10 HPF and no malignant cells were found in this preparation.

**Conclusion of material 2:** Myomectomy is Uterine myoma.

## **DISCUSSION**

Uterine leiomyomas are the most common benign disease of reproductive-aged women. However, the retroperitoneal region is a rare location for leiomyoma development. There are just a few case reports describing retroperitoneal leiomyoma in the literature. Moreover, retroperitoneal (intrasacrouterina ligament) leiomyoma is even rare. In this case report, we presented a case that developed a pedunculated retroperitoneal leiomyoma in the cavum pelvis intrasacrouterina ligament. This case is like the other evidence of myxoid leiomyoma in retzius and paravaginal regions<sup>3</sup>. The pre-operative ultrasonography diagnosis only presented pedunculated myoma uterine, as in Figure 1.

Uterine myomas are frequently detected during a pelvic examination. Myomas usually arise from uterine smooth muscle fibers and localize submucously, intramurally, or subserosally. Nevertheless, they can also be found on the cervix, broad ligaments, or ovaries. Less frequently, nodules that arose from smooth muscle are observed on peritoneal

surfaces. Myomas are seen in 20% of the reproductive age range, but in people older than 40 who have no symptoms, the figure rises to 40-50 percent<sup>45</sup>. We report a case in this article with 46 who have two live children and regular menses. She complains of left abdominal pain and penetrating to the waist. There were no complaints of defecation or urination. It differs from the case report of a myoma atypically localized on the serosa of the sigmoid colon<sup>4</sup>.

After an incision is made, the abdominal wall and abdominal cavity are exposed. It obtained a fixed uterine mass with a shift to the right side. There was difficulty during the hysterectomy, bleeding from the uterine arteries. After the uterine mass was removed, the pelvic cavity still looked bulging and hard. Retroperitoneal bleeding is suspected, as appears in Figure 2a. After consultation with the general surgeon, a puncture was performed in the bulging area, and the bleeding was rather heavy. Subsequently, an incision was made in the bulging area, and a shiny white mass was seen; as seen in Figure 2b, the incision was raised, and the uterine myoma was intrasacrouterina ligament removed by myomectomy in Figure 2c. Bachev uses a different approach when performing intraligament uterine myoma surgery on ligament broad ligament using laparoscopy hysterectomy with ablatic vaginal morcellation of the specimen in endobag<sup>6</sup>.

Uterine leiomyomas are benign tumors arising from uterine smooth muscle. Although their pathogenesis remains unclear, they are the most common tumor of the female reproductive tract, occurring in half of the women older than 35 years. Uterine leiomyomas represent the most common benign tumors of the female reproductive tract. Giant uterine lei-

myomas are uncommon and pose a difficult diagnosis and treatment challenge. Uterine leiomyoma is one of the most common tumors, with 20-40% of women of reproductive age being diagnosed with it. Until they reach the age of 50, over 70% of white women and less than 80% of black women will have had at least one leiomyoma<sup>57</sup>. The frequency of the emergence of uterine leiomyoma in black women is significantly higher than in white women<sup>5</sup>. This case needs to help complain of pain, especially during menses. After removal of uterine myoma and anatomical pathology examination, uterine myoma and intrauterine Adenomyosis were found in Figure 3. In this case, Adenomyosis is different from the findings of İslimye Taşkın, who got Adenomyosis in the broad ligament<sup>8</sup>.

## CONCLUSION

This case report is an infrequent case. Intraligamentary uterine fibroids found most often are in the broad ligament. In this case, the intraligamentary uterine myoma was found in the sacrouterine ligament, which is a pedunculated uterine myoma. There was a discrepancy between the preoperative diagnosis and the operative diagnosis, so exploration and appropriate approaches are needed to evacuate uterine myomas.

## Acknowledgments

The authors thank the Director of RSI Hasanah Muhammadiyah Mojokerto, Indonesia, for providing the opportunity to serve the patient and The Dean of the Medical Faculty of Universitas Muhammadiyah Surabaya, East Java, Indonesia, for facilitating this study.

## REFERENCES

1. McLucas B. Diagnosis, imaging and anatomical classification of uterine fibroids. *Best Pract Res Clin Obstet Gynaecol.* 2008;22(4):627–42.
2. Joy E. Olotu, Michael Okon. Anatomical location of uterine fibroids among women attending a tertiary health facility in a southern Nigerian population. *GSC Biol Pharm Sci.* 2021;14(2):007–15.
3. Dursun P, Altuntafl B, Ayhan A. Retroperitoneal Ve Paravajinal Miksoid Leiomyoma. *Türk Jinekolojik Onkol Derg.* 2007;10(2):51–3.
4. Yilmazer M, Kaya C, Dernalrel C, Erdogan N, Dincer Cengiz S. Sigmoid Kolon Serozasında A Tipik Lokalizasyonlu Myoma Uteri Myoma of ATypical Localization on The Serousa of Sigmoid Colon. *Med J ofKocatepe.* 2001;2:283–5.
5. Cărăuleanu A, Socolov R, Lupaşcu IA nghelach., Rugină V, Socolov D. Giant Intraligamentary Uterine Leiomyoma and Its Complications. *Rev medico-chirurgicală a Soc Medici și Nat din Iași.* 2016;120(1):145–51.
6. Bechev B, Magunska N, Kovachev E, Ivanov S. Laparoscopic Treatment of Intraligamentary Leiomyoma Per Magna. *Akush Ginekol (Sofia).* 2016;55(1):66–8.
7. Chrisostomos S, Evaggelos D, Konstantinos Z. Enormous Intraligamentary Uterine Fibroids in Young Patient-Laparoscopic Approach. *Open Access J Gynecol Obstet.* 2019;2(2):17–20.
8. İslimye Taşkın M, Adalı E, Güleç Başer B, Uzgören E. Intraligamentary Adenomyoma. *Balıkesir Heal Sci J [Internet].* 2015 Aug 31 [cited 2021 Dec 5];4(2):107–10. Available from: <https://dergipark.org.tr/en/pub/balikesirsbd/452324>